SonoPath
Clinical Sonography & Telecytology

EDUCATIONAL TELECONSULTATION SERVICES™

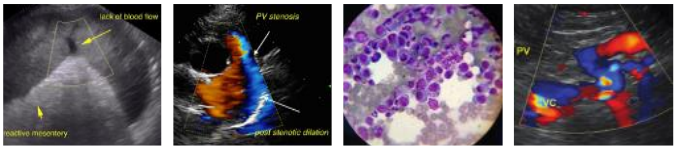

SonoPath.com™
1-800-838-4268 info@sonopath.com

PATIENT
Goliath Page

SPECIES
Feline

BREED
DSH

SEX
Male Neutered

AGE
15 years

WEIGHT
10.6lbs

INTERPRETED BY
Maggie Machen Lamy, DVM, DACVIM (Cardiology)

IMAGING PERFORMED BY
Dana Alterman, RDCS, LVT

HOSPITAL NAME
Eubank Animal Clinic

REFERRING VET
Dr. Benham

INVOICE
31453

DATE
6/20/23

PRESENTING CLINICAL SIGNS
History: Recheck echo. Grade 4/6 heart murmur. CKD stage 2-3. Asses prior to dental.
-Pertinent previous echo findings (1/2022): Mild LVH, LVOTO, mild AI.

ELECTROCARDIOGRAPHIC FINDINGS
A six lead ECG is available at 50mm/s; 10mm/mV. The average heart rate is 240bpm (range 230-250bpm). The rhythm is sinus in origin, with a p for every QRS complex and vice versa. The P wave morphology is positive with a normal dimension. Normal PR. The QRS is inverted. The MEA is shifted left. No ectopic beats, pauses or dysrhythmias observed.
ECG diagnosis: Sinus tachycardia with an LAFB.

ECHOCARDIOGRAM FINDINGS
2D, m-mode, color flow and doppler imaging is available. The left ventricular wall is mildly increased in dimension. There is a diffusely hyperechoic endocardium consistent with fibrosis. Mild symmetric papillary muscle hypertrophy and remodeling. The right ventricle is subjectively normal in size and morphology. There is mild left atrial enlargement present. No right atrial enlargement present. Mildly elevated RVOT velocity. Trace TR. Normal LVOT velocity. There is no obvious systolic anterior motion (SAM) of the mitral valve present. Mild AI. No MR. Scant pericardial effusion suspected in some views, although the finding is inconsistent. No pleural effusion appreciated. No obvious cardiac tumors.

CARDIAC CHART

FELINE CARDIAC PARAMETERS	BODY WEIGHT (kg)	HR (BPM)	IVSd (cm) (Moise, Pipers)	LVIDd (cm) (Moise, Pipers)	LVWd (cm) (Moise, Pipers)	FS (%)	EF (%)
NORMAL PARAMETER	------	150-240	0.35-0.55	<2 (mean 1.5)	3.5-0.55	35-67	80-100
PATIENT	4.8	NM	0.69	1.34	0.67	52	86
FELINE CARDIAC PARAMETERS	LA/AO (Boon)	LA/AO HEART BASE (Swe) (Abbott)	LA 2D short axis Base view (cm) (Abbott)		LVOT VEL (m/s)	RVOT VEL (m/s)	E max (m/s)
NORMAL	<1.5	<1.3	<1.2		<1.6	<1.3	<0.9
PATIENT	NM	1.36	1.36		1.8	2.5	NM

**Note: All measurements based upon multi-modal images and methods. An average value is reported.*
Adapted from June Boon, Veterinary Echocardiography,1998
Abbott J & MacLean H JVIM 2006;20: 111-119, Moise et al. Am J Vet Res 47:1476, 1986. Pipers et al. Am J Vet Res 40:882, 1979.

INTERPRETATION OF THE FINDINGS & FURTHER RECOMMENDATIONS
Hypertrophic cardiomyopathy (HCM) is a rule out diagnosis once a patient is deemed normotensive and euthyroid. Both should be considered in this cat with reported renal disease. Regardless, what is seen here is mild, with only mild LVH and mild LA dilation. This would indicate the risk for clinical issues is low at this time. The previously noted LVOT is not apparent; however, a dynamic RVOT obstruction is confirmed as the cause of the murmur. This is a benign flow abnormality secondary to tachycardia. Along that same line, sinus tachycardia is noted on the ECG. Finally, scant pericardial effusion is suspected in some views, although the finding is inconsistent. This is certainly noncardiac in origin and systemic evaluation may be warranted in

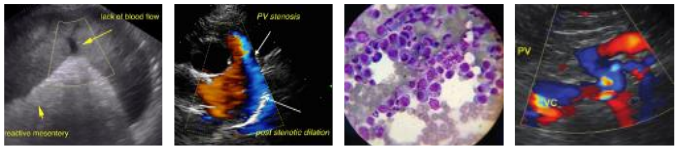

SonoPath.com
1-800-838-4268 info@sonopath.com

PATIENT
Goliath Page

SPECIES
Feline

BREED
DSH

SEX
Male Neutered

AGE
15 years

WEIGHT
10.6lbs

INTERPRETED BY
Maggie Machen Lamy, DVM, DACVIM (Cardiology)

IMAGING PERFORMED BY
Dana Alterman, RDCS, LVT

HOSPITAL NAME
Eubank Animal Clinic

REFERRING VET
Dr. Benham

INVOICE
31453

DATE
6/20/23

this senior cat. Finally, with any AI a BP is highly recommended. No additional issues are identified.

No medications are indicated prior to significant atrial dilation. It is important to note that no medications have been shown to definitively alter long term outcome at this stage, particularly in the absence of SAM.

Monitor at home for any respiratory issues or signs of blood clot events (neurologic change, paralysis, etc.). Anesthetic risk is considered mild, however judicious fluid administration is advised if needed with careful RR/RE monitoring to screen for fluid overload. Additionally, drugs that stimulate heart rate should be avoided unless clinically necessary (glycopyrrolate, atropine). Risk for complication with steroid use typically follows LA dilation, which in this case is mildly elevated. If needed, monitoring of RR/RE is advised particularly in the initiation phase.

PLAN

A screening blood pressure and T4 are recommended, then every 6 months lifelong.

A recheck echocardiogram is recommended in 6 months to assess for progression, sooner if any issues arise in the interim.

IMAGES

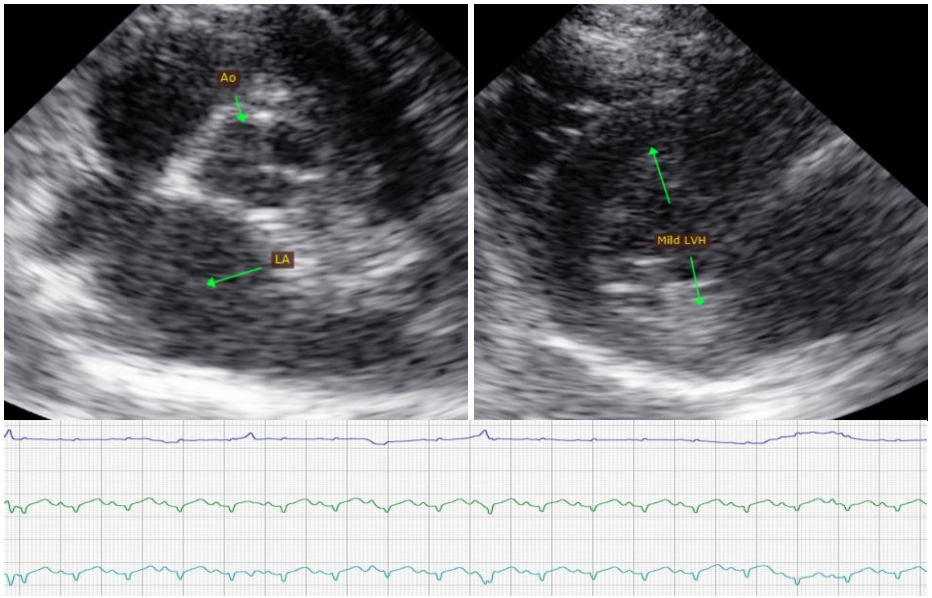

The information and recommendations provided are based on the images presented by the referring veterinarian. No evaluation can be communicated regarding pathology that was not visible in the image/video clips provided.

Thank you for this referral. This report was generated using transcription software, and minor dictation errors may be present. If the clinical or image interpretation does not parallel your findings or if I can be of any further assistance, please contact me.

Maggie Machen Lamy, DVM
Diplomate of the American College of Veterinary Internal Medicine (Cardiology)
info@sonopath.com